

Grand Rounds Vol 5  
Speciality: Gastroenterology  
Article Type: Case Report  
DOI: 10.1102/1470-5206.2005.0010  
© 2005 e-MED Ltd

# A case report of Boerhaave's syndrome

Sreekanth Reddivari, Carlo Nunes, Emyr Humphries  
and Christopher Fox

*William Harvey Hospital, East Kent NHS Trust, UK*

Date accepted for publication 15 February 2005

## Abstract

We report a case of Boerhaave's syndrome in a previously fit 57-year-old lady with an aetiological association with a co-existing duodenal ulcer. We discuss the diagnostic difficulties presented by this case, the importance of prompt diagnosis and intervention, and the problems involved in the management that are highlighted in this case. This is an extremely rare but well recognised entity. A 1980 review by Kish cited only 300 cases worldwide; a small percentage were diagnosed post mortem (John BE, Zua MS. Boerhaave's syndrome—an elusive diagnosis. *Tenn Med* 1997; 90: 56–8).

## Keywords

Spontaneous rupture of the oesophagus; oesophageal perforation; transmural perforation of the oesophagus; emesis complications.

[Abstract](#)

[Keywords](#)

[Case report](#)

[Follow up](#)

[Further plan](#)

[Unusual features](#)

[Teaching point](#)

[References](#)

[Figure 1](#)

[Figure 2](#)

[Figure 3](#)

[Figure 4](#)

[Home Page](#)

[Title Page](#)

[◀](#)

[▶](#)

[◀](#)

[▶](#)

[Go Back](#)

[Full Screen](#)

[Close](#)

[Quit](#)

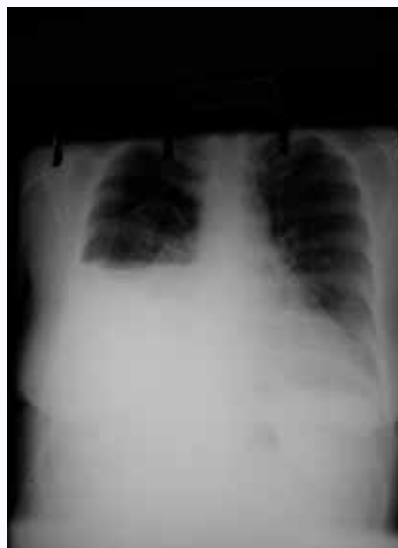# GR

## Case report

A 57-year-old lady, previously fit and well, presented with a 12-h history of intermittent epigastric pain associated with nausea, retching and vomiting<sup>[1]</sup>. On retrospective history there had also been a brief episode of right hypochondrial pain radiating to the back and right shoulder; which was not volunteered on admission and it was overshadowed by the epigastric pain and nausea. She was admitted under the general surgeons with a provisional diagnosis of probable gastritis or acute cholecystitis and was kept nil by mouth. Laboratory results were all within normal limits except for a mild leukocytosis with a neutrophilia. Initial plain abdominal and chest radiography were normal apart from non-specific shadowing in the right lower zone. An ultrasound abdomen was normal and her symptoms resolved with antiemetics, analgesia and intravenous fluids. Vital observations were normal. Oral fluids and soft diet were reintroduced with a view to discharge if tolerated. A few hours prior to the planned discharge she complained of dyspnoea and right lower thoracic pain. Examination revealed a trachea deviated to the left and signs of a pneumothorax on the right. An urgent chest X-ray confirmed a right hydropneumothorax with signs of tensioning (Fig. 1). A chest drain was inserted urgently and the pleural fluid drained appeared grey-black. Urgent analysis of the fluid was requested. Due to blockage of the initial chest drain it was replaced with a wider bore drain, allowing drainage of a thick dark material. She was kept nil by mouth with the institution of broad-spectrum antibiotics, oxygen supplementation and intravenous fluids. Urgent computed tomography (CT) scanning of the chest and abdomen was arranged and the pleural fluid was sent for urgent microscopy (Figs. 2 and 3). Microscopy confirmed food residue and subsequent culture was consistent with oral type flora. The CT scan of the chest with oral contrast revealed a left hydropneumothorax and a contrast leak into the right pleural space. This was immediately followed up with a Gastrograffin swallow, which showed a 15 mm tear in the lower third of the oesophagus communicating with the right pleural cavity (Fig. 4). The diagnosis of oesophageal rupture was thus confirmed and she was transferred to a tertiary cardiothoracic centre for further management.

[Abstract](#)
[Keywords](#)
[Case report](#)
[Follow up](#)
[Further plan](#)
[Unusual features](#)
[Teaching point](#)
[References](#)
[Figure 1](#)
[Figure 2](#)
[Figure 3](#)
[Figure 4](#)
[Home Page](#)
[Title Page](#)
[◀](#)
[▶](#)
[◀](#)
[▶](#)
[Go Back](#)
[Full Screen](#)
[Close](#)
[Quit](#)

# GR



**Fig. 1.** Hydropneumothorax with a large bore chest drain in situ. No pneumo-mediastinum evident. No V-sign of Naclerio (present in 20% of cases), which consists of radioluscent streaks of air that dissect the fascial planes behind the heart to form the shape of the letter V. It is a specific although insensitive radiographic sign.

## Follow up

A decision was taken to treat conservatively<sup>[2]</sup> as the diagnosis was confirmed more than 5 days after initial presentation. She was kept nil by mouth and was started on total parental nutrition (TPN) as a bridge to jejunostomy feeding. There is evidence that jejunostomy<sup>[3,4]</sup> feeding improves outcome in conservatively treated Boerhaave's syndrome. Her in-patient stay was soon complicated by a further episode of emesis and acute abdominal pain. A chest X-ray revealed the possibility of a perforated viscus and a

Abstract

Keywords

Case report

Follow up

Further plan

Unusual features

Teaching point

References

Figure 1

Figure 2

Figure 3

Figure 4

Home Page

Title Page

◀

▶

◀

▶

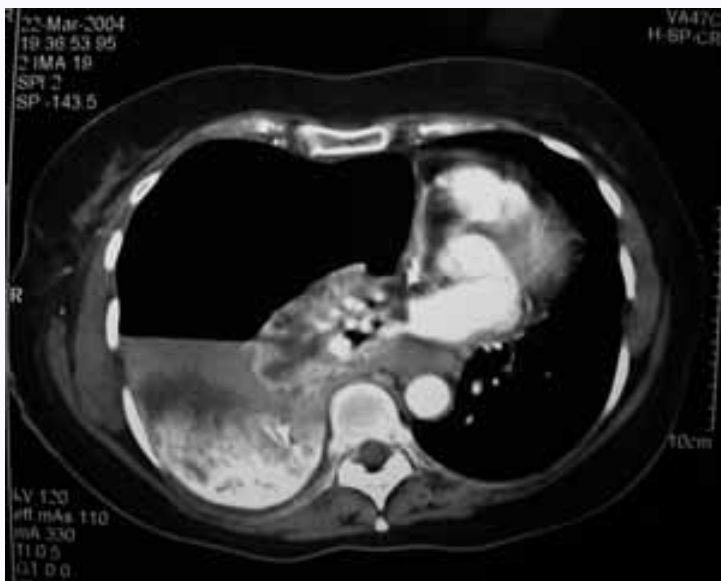Go Back

Full Screen

Close

Quit

GR



**Fig. 2.** CT scan shows contrast in the right pleural cavity. The collapsed lung and right hydropneumothorax can also be seen. A disadvantage with CT scanning is localising the oesophageal tear.

laparotomy was performed. A perforated duodenal ulcer, which in retrospect seems to be the reason for her epigastric pain and vomiting even at initial presentation, was found and a primary repair was done with simultaneous insertion of a jejunostomy feeding tube. This necessitated a long in-patient stay and after 8 weeks she remained stable. The right lung had completely re expanded. There is a small residual right pleural effusion. Unfortunately healing of the oesophageal tear remained unsatisfactory and repeat Gastrografin swallows demonstrated the persistence of a 12 mm tear communicating with the right pleural cavity. She had a gastrojejunal feeding tube inserted in a tertiary care centre and was managed

[Abstract](#)

[Keywords](#)

[Case report](#)

[Follow up](#)

[Further plan](#)

[Unusual features](#)

[Teaching point](#)

[References](#)

[Figure 1](#)

[Figure 2](#)

[Figure 3](#)

[Figure 4](#)

[Home Page](#)

[Title Page](#)

◀◀

▶▶

◀

▶

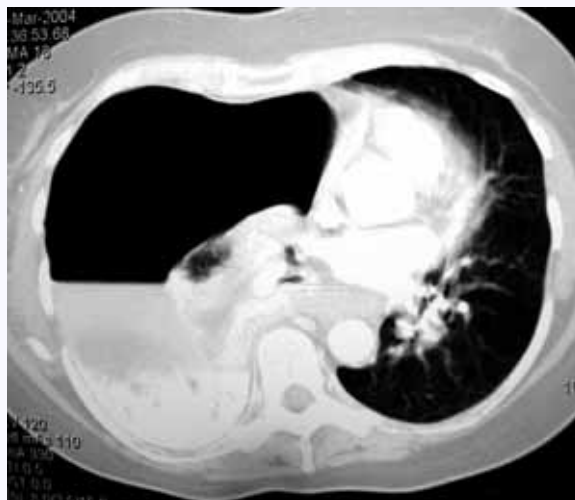[Go Back](#)

[Full Screen](#)

[Close](#)

[Quit](#)

GR



**Fig. 3.** A further CT image.

conservatively with periodic Gastrograffin swallows. Healing was slow and she was referred to another tertiary centre for consideration of a repair. A repeat swallow that was done at the end of August showed that the oesophagus had mended and the feeding tube was ultimately removed in October. She remains well at the time this report was submitted.

### Further plan

If the tear had not healed then further options would have included:

- Surgical repair: there are cases where late surgical repair has been undertaken with success<sup>[5,6]</sup>.

[Abstract](#)

[Keywords](#)

[Case report](#)

[Follow up](#)

[Further plan](#)

[Unusual features](#)

[Teaching point](#)

[References](#)

[Figure 1](#)

[Figure 2](#)

[Figure 3](#)

[Figure 4](#)

[Home Page](#)

[Title Page](#)

◀

▶

◀

▶

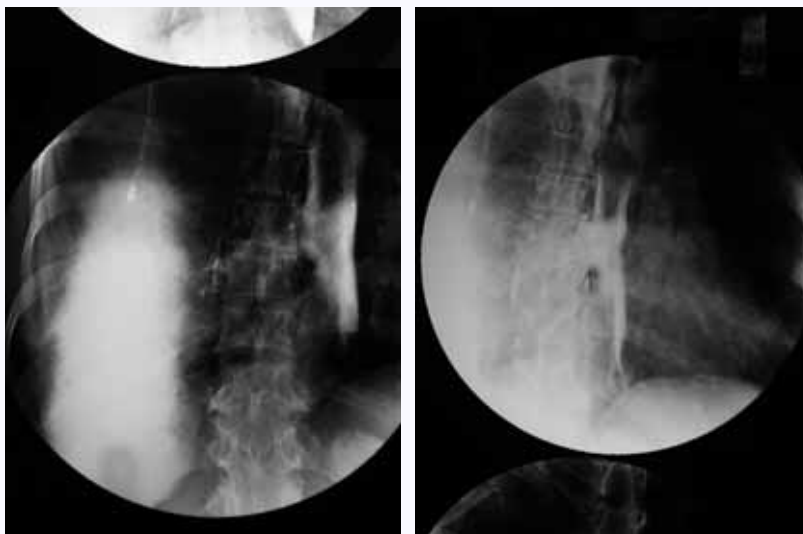
[Go Back](#)

[Full Screen](#)

[Close](#)

[Quit](#)

GR



**Fig. 4.** Gastrograffin swallow demonstrates the tear in the oesophagus (arrows) communicating with the right pleural cavity. A portex chest drain can also be seen. Contrast swallow (water soluble) is the gold standard in diagnosis and follow up in Boerhaave's syndrome. Barium is contraindicated. A barium swallow can be used if the Gastrograffin swallow is normal and the clinical suspicion is high.

- Endoscopic intervention<sup>[7,8]</sup>: T-tube/self-expandable mesh stent/self-expandable plastic covered metal stents to bridge the tear; this has been used in many cases where there was a delay in the diagnosis. The risks of stent migration with subsequent complications must be taken into consideration. The prospect of a biodegradable stent is currently under active research and this may become the preferred method of treatment in all cases in the future.
- Thoracoscopic repair<sup>[9]</sup>.

[Abstract](#)

[Keywords](#)

[Case report](#)

[Follow up](#)

[Further plan](#)

[Unusual features](#)

[Teaching point](#)

[References](#)

[Figure 1](#)

[Figure 2](#)

[Figure 3](#)

[Figure 4](#)

[Home Page](#)

[Title Page](#)

◀

▶

◀

▶

[Go Back](#)

[Full Screen](#)

[Close](#)

[Quit](#)

GR

## Unusual features

The absences of typical features of Boerhaave's syndrome in the initial presentation led to a delayed diagnosis in this case. Left posterolateral oesophageal perforation is the more common site in adults. Subcutaneous or mediastinal emphysema is usually a feature but absent in this case. About 90% of the initial chest radiographs raise the suspicion of Boerhaave's syndrome, which was absent in this particular case. Most often there is a history of alcohol excess or overindulgence of food with vomiting.

## Teaching point

A high degree of clinical suspicion is a pre-requisite for the prompt diagnosis and management of this condition in order to prevent the associated morbidity and mortality. Time is of absolute importance in the management and prognosis is directly contingent with early recognition and appropriate intervention.

This is the most lethal perforation of the gastrointestinal tract (estimated 40% mortality), with the best results after early recognition and intervention. Delay in intervention relates directly to increased mortality. If more than 24 h, mortality is greater than 50%; if more than 48 h, mortality is greater than 90%. Surgical intervention after 72 h has not been reported to be beneficial. Herman Boerhaave, a Dutch physician, first described this syndrome in 1724. Until 1947, the mortality rate nearly always approached 100%.

## References

1. Jagminas L, Silverman RA. Boerhaave's syndrome presenting with abdominal pain, emesis and right hydropneumothorax. Am J Emerg Med 1996; 14: 53-6. [MEDLINE Abstract](#)
2. Troum S, Lane CE, Dalton ML Jr. Surviving Boerhaave's without a thoracotomy. Chest 1994; 106: 297-9. [MEDLINE Abstract](#)

[Abstract](#)
[Keywords](#)
[Case report](#)
[Follow up](#)
[Further plan](#)
[Unusual features](#)
[Teaching point](#)
[References](#)
[Figure 1](#)
[Figure 2](#)
[Figure 3](#)
[Figure 4](#)
[Home Page](#)
[Title Page](#)
[◀](#)
[▶](#)
[◀](#)
[▶](#)
[Go Back](#)
[Full Screen](#)
[Close](#)
[Quit](#)

3. Kallis P, Belsham PA, Pepper JR. Spontaneous rupture of the oesophagus: conservative versus surgical treatment. *J R Soc Med* 1991; 84: 690-1. [MEDLINE Abstract](#)
4. Salim AS. Jejunostomy feeding for the conservative management of spontaneous rupture of the oesophagus. *Br J Clin Pract* 1991; 45: 37-40. [MEDLINE Abstract](#)
5. Lawrence DR, Ohri SK, Moxon RE, Townsend ER, Fountain SW. Primary esophageal repair for Boerhaave's syndrome. *Ann Thorac Surg* 1999; 67: 818-20. [MEDLINE Abstract](#)
6. Sakamoto Y, Tanaka N, Furuya T *et al.* Surgical management of late oesophageal perforation. *Thorac Cardiovasc Surg* 1997; 45: 269-72. [MEDLINE Abstract](#)
7. Dumonceau JM, Deviere J, Cappello M, Van Gossum A, Cremer M. Endoscopic treatment of Boerhaave's syndrome. *Gastrointest Endosc* 1996; 44: 477-9. [MEDLINE Abstract](#)
8. Eubanks PJ, Hu E, Nguyen D, Procaccino F, Eysselein VE, Klein SR. A case of Boerhaave's syndrome successfully treated with a self-expandable wire mesh stent. *Gastrointest Endosc* 1999; 49: 780-3. [MEDLINE Abstract](#)
9. Scott HJ, Rosin RD. Thoracoscopic repair of a transmural perforation of the oesophagus. *J R Soc Med* 1995; 88: 414-15.

[Abstract](#)
[Keywords](#)
[Case report](#)
[Follow up](#)
[Further plan](#)
[Unusual features](#)
[Teaching point](#)
[References](#)
[Figure 1](#)
[Figure 2](#)
[Figure 3](#)
[Figure 4](#)
[Home Page](#)
[Title Page](#)
[◀◀](#)
[▶▶](#)
[◀](#)
[▶](#)
[Go Back](#)
[Full Screen](#)
[Close](#)
[Quit](#)
