

Oedematous Bauhinitis: a rare endoscopic diagnosis in ileocaecal disease

C. J. Krones[†], J. Conze[†], J. Grommes[†], S. Truong[†], H. Griefingholt[‡]
and V. Schumpelick[†]

[†]*Department of Surgery, Medical Faculty, RWTH Aachen, Germany*

[‡]*Institute of Pathology of the Medical Faculty, RWTH Aachen, Germany*

*Corresponding address: Dr C J Krones, Department of Surgery, RWTH Aachen,
Pauwelsstr. 30, 52057 Aachen, Germany*

Tel.: +49 241 80 89 500/01; fax: +49 241 80 82 41 7; E-mail: ckrones@ukaachen.de

Date accepted for publication 22 February 2005

Abstract

Isolated Bauhinitis is a rare cause of non-specific abdominal symptoms in adults. Modern descriptions of the disease are lacking. We report two current cases with an overview of the literature and a discussion of the aetiology, clinical signs, diagnostic findings, and treatment guidelines. Colonoscopic and histological findings are used to diagnose the condition. Conservative treatment is the mainstay of management, but recurrent symptoms often lead to the necessity for ileocaecal resection.

Keywords

Oedematous Bauhinitis; ileocaecal diseases; colonoscopy.

Introduction

[Bauhinitis is a German term describing inflammation of the ileocaecal valve—the valve of Bauhin (Editor's note).] Isolated oedematous Bauhinitis is a rare disease mimicking recurrent ileocaecal intussusception in adults. First described in 1953^[1], the international literature contains only a few papers from the 1960s and 1970s^[1–8], mainly written in French. Modern descriptions of the disease are lacking. However, the differential diagnosis includes conditions such as benign and malignant endothelial tumours, lymphomata, chronic inflammation of the gastrointestinal tract such as Crohn's disease and infective diseases such as tuberculosis, all of which require specific aggressive therapy. With advanced diagnostic technology, routine endoscopy usually leads to an easy, safe and reliable diagnosis of an isolated oedematous Bauhinitis without further invasive investigations. This paper summarises the information available about this rare disease and provides an overview of the clinical presentation, aetiology and pathology, and offers diagnostic and treatment guidelines.

Case histories

Case 1

A 41-year-old woman presented with recurrent colicky pain in the right iliac fossa accompanied by vomiting. Bowel movements were regular. The past medical history included appendectomy

This paper is available online at <http://www.grandrounds-e-med.com>. In the event of a change in the URL address, please use the DOI provided to locate the paper.

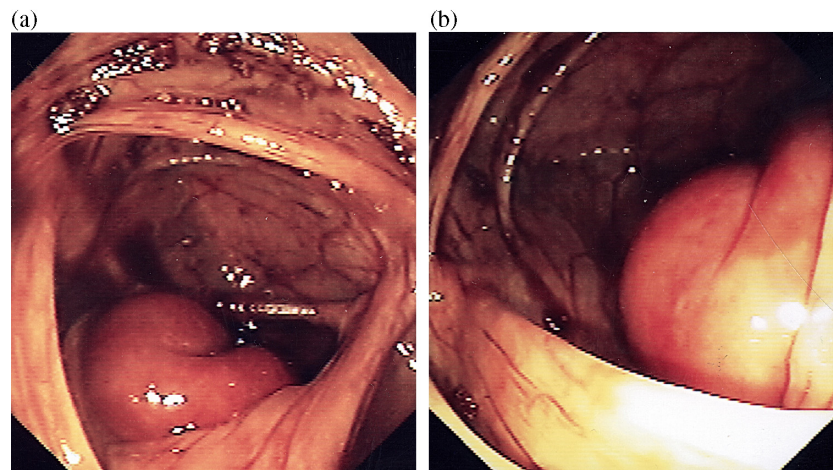


Fig. 1. Colonoscopy reveals an isolated swelling of Bauhin's valve without any further ileocaecal pathologies.

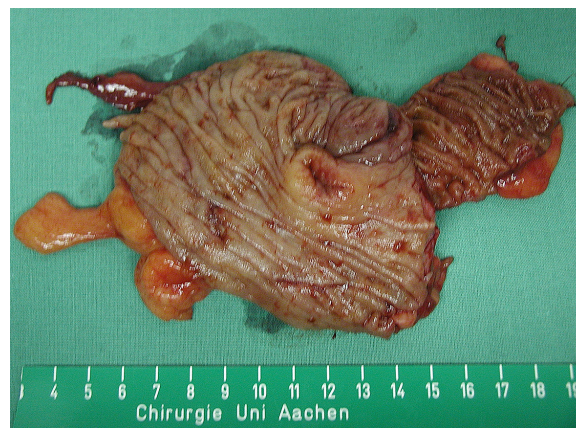


Fig. 2. Ileocaecal resection confirms the isolated swelling of Bauhin's valve.

and laparoscopic adhesiolysis several years previously. On physical examination, there was localised abdominal tenderness without guarding. Bowel sounds were normal. Apart from a borderline leucocytosis, laboratory and radiological tests were normal. An ultrasound of the abdomen showed a discrete mass involving the ileocaecal valve, narrowing the intestinal lumen. Colonoscopy confirmed the diagnosis of Bauhinitis, demonstrating isolated swelling of the caecal valve (Fig. 1(a), (b)). Conservative treatment with antispasmodics drugs, laxatives and parenteral feeding was successful initially, but 10 days after admission symptoms returned. A repeat computed tomography (CT) scan demonstrated pseudo-tumorous inflammation of the ileocaecal valve as before. At explorative laparotomy, no other pathology was found (Fig. 2) and an ileocaecal resection was performed. The operation and the subsequent clinical course were uncomplicated. Histopathology showed submucosal oedema strictly limited to Bauhin's valve, accompanied by a mild inflammation of the mucosa layer (Fig. 3).

Case 2

A 43-year-old man presented as an emergency admission with acute pain in the right iliac fossa. Bowel movements were regular and there was no vomiting. The patient had not had any previous surgery. On physical examination localised abdominal tenderness without guarding was found. Bowel sounds were normal. Laboratory tests showed a minor leucocytosis and a small increase in C-reactive-protein. Routine radiological imaging was normal. Ultrasound of the abdomen showed an undefined abnormality of the caecum. Colonoscopy demonstrated isolated swelling of the caecal valve,

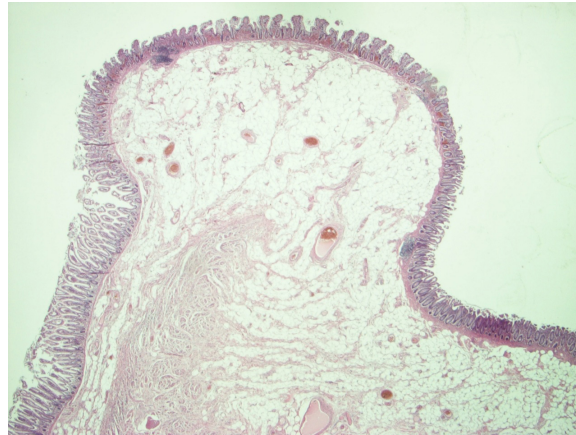


Fig. 3. Isolated submucosal oedema of Bauhin's valve in the absence of inflammatory infiltrations (H&E, 12.5×).

supporting the diagnosis of Bauhinitis. Histological samples revealed non-specific inflammation of Bauhin's valve. Conservative treatment was unsuccessful and an exploratory laparotomy was performed. The appendix and all other intra-abdominal organs were normal and an ileocaecal resection was done. The operation and the subsequent clinical course were uncomplicated. Histopathological findings confirmed the diagnosis of an isolated Bauhinitis.

Discussion

Following the work of Auvillain, Debray defined oedematous Bauhinitis as a diagnostic entity in caecal disease in 1953^[1]. Debray's four diagnostic criteria are: (a) chronic diarrhoea without fever, blood, or mucus; (b) specific radiological findings (lacuna-like cockade or epsilon profile); (c) oedema strictly limited to the ileocaecal valve; and (d) histological findings of oedema in the submucosal layer, accompanied by non-specific inflammation of Bauhin's mucosa. In 1971, Grosdidier *et al.* recognised the anatomical and histological criteria as being essential for the diagnosis, with diarrhoea as a less prominent feature^[3]. The current gastroenterological literature contains no description of this rare disease.

The cause of isolated oedematous Bauhinitis remains unknown. Consequently, the diagnosis still depends to a considerable degree on the exclusion of tumours, infection, or specific inflammatory disease. The disease seems to be much more common in adults; there is only one reported case in a child^[9]. Our findings support this presumption.

Colonoscopic findings consist of an isolated generalised swelling of the ileocaecal valve. Other pathologic findings are absent, apart from occasional mild and superficial erosions of the overlying mucosa. It is usually impossible to pass the colonoscope past the ileocaecal valve because of oedema. The endoscopic picture is diagnostic, when accompanied by the typical histopathological findings of isolated submucosal oedema. Clinical findings vary from constipation to diarrhoea and acute to chronic pain in the right iliac fossa, but are mainly non-specific. Abdominal ultrasound will support the endoscopic findings when there is homogenous oedema of the ileocaecal valve accompanied by a central hypoechoic mass. Normally, the swollen ileocaecal valve narrows the intestinal lumen. Radiological imaging including computed tomography can confirm the diagnosis but cannot replace endoscopy.

The histopathological findings are well defined. There is a mild and non-specific inflammation of Bauhin's mucosa with local oedema which is strictly limited to the submucosa of the ileocaecal valve. The histological changes in themselves are not sufficiently severe to support the diagnosis in the absence of positive endoscopic findings.

The early publications mainly recommend conservative treatment with antispasmodic drugs, oral application of bismuth, and antihistamines or antibiotics as indicated. Most reports recommend operative resection for persistent symptoms. Provided that endoscopy excludes malignancy, the mainstay of treatment still remains conservative with parenteral nutrition, laxatives, antispasmodics and anti-inflammatory drugs. Conservative treatment often fails and resection usually becomes necessary. Schlosser *et al.*^[6] recommend a right hemicolectomy but we prefer a more limited ileocaecal resection.

Teaching points

Isolated Bauhinitis is a rare condition, occurring mainly in adults, which should be considered in the differential diagnosis of right iliac fossa pain. Colonoscopic examination with histological confirmation is diagnostic. The diagnosis can be confirmed by abdominal ultrasound or CT scan. According to the nature of the disease, a conservative approach is justified, but often proves unsuccessful. In case of recurrent symptoms, local ileocaecal resection is indicated.

References

1. Debray C, Duval R, Roge J. Bauhinite oedemateuse: oedeme inflammatoire pseudo-tumoral de la valvule de Bauhin. *Arch Mal Appar Dig* 1953; 42: 163.
2. Arguello M, Thys O, Engelholm L *et al.* Edematous hypertrophy of Bauhin's valve. Three surgical cases. *Acta Gastroenterol Belg* 1967; 30: 812.
3. Grosdidier J, Pierson B, Richaume B, Boissel P. Inflammatory pathology of Bauhin's valve. Edematous bauhinitis. *Ann Chir* 1972; 26: 677.
4. Legre L, Tronconi JC, Vianet E, Monges A. Remarks on edematous bauhinitis. *Arch Fr Mal App Dig* 1971; 60: 480.
5. Paris J, Quandalle P, Paris JC *et al.* Recurrent ileo-ceco-colonic invaginations and edematous bauhinitis. *Sem Hop* 1974; 50: 2533.
6. Schlosser GA, Borner C, Schreiber HW. Bauhin's valve syndrome. *Zentralbl Chir* 1982; 107: 707.
7. Yanev S, Elenkov P. Allergic terminal ileitis and edematous bauhinitis. *J Radiol Electrol Med Nucl* 1968; 49: 237.
8. Yvergneaux E, Yvergneaux JP. Edematous bauhinitis. *J Belge Radiol* 1969; 52: 6.
9. Sztaba R, Karcz J. Edematous inflammation of the ileocecal valve in a child. *Pol Tyk Lek* 1970; 25: 1952.